

Review Article

Collagen – structure, function and distribution in orodental tissues

Zaneta D'souza, Tabita Joy Chettiankandy, Manisha S. Ahire (Sardar), Arush Thakur, Sarang G. Sonawane, Anuradha Sinha
Department of Oral Pathology and Microbiology, Government Dental College and Hospital, Mumbai, Maharashtra, India.



*Corresponding author:

Arush Thakur,
Ex-Assistant Professor,
Department of Oral Pathology
and Microbiology, Government
Dental College and Hospital,
Mumbai, Maharashtra, India.
arushthakur.medico@gmail.com

Received : 06 January 20
Accepted : 20 January 20
Published : 29 February 20

DOI
10.25259/JGOH_4_2020

Quick Response Code:



ABSTRACT

Collagens are a large family of triple helical proteins which are found extensively throughout the body. They form the basic framework of the extracellular matrix providing support and form to cells and tissues. They are important for various functions such as angiogenesis, morphogenesis, cell adhesion, repair, and regeneration. In this article, we have focused our discussion to the structure, the synthesis, and the degradation of collagen followed by its distribution and function in various oral tissues.

Keywords: Collagen, Matrix metalloproteinases, Extracellular matrix

INTRODUCTION

Collagens are a large family of triple helical proteins which are found extensively throughout the body and are necessary to perform various functions such as tissue scaffolding, cell adhesion, cell migration, angiogenesis, tissue morphogenesis, and tissue repair.^[1] The word “collagen” is derived from Greek word – “kolla” and “gen” (*kolla* – glue and *gen* – producer). They are a group of fibrous proteins that occur in vertebrates as the chief constituent of connective tissue fibrils and in bones.^[2] Since they form the basic framework of tissues of the body and more importantly the oral tissues, it is necessary to understand their formation, structure and composition to better evaluate the pathologies associated with them.

HISTORY, STRUCTURE AND COMPOSITION

Collagen is a complex molecule, the structure of which has been revised over the years. Astbury and Bell (1940) stated that collagen is a single extended polypeptide chain which has amide bonds, while Pauling and Corey (1951) stated that it was made up of three polypeptide chains held by hydrogen bonds.^[3,4] Years later, in 1954, Ramachandran and Karta from Madras studied and put forward a structure which is widely accepted even today. They described the structure as that having, 3- α -polypeptide chains which are coiled around each other to form a right-handed triple helix. This model was called the Madras model as it was first described in Madras.^[5] The three polypeptide chains could be identical (homotrimers) as in collagens II, III, VII, VIII, X and others or could be different (heterotrimers) as in collagen Types I, IV, V, VI, IX and XI.^[6] Each of these chains shows a repetitive sequence of amino acids with glycine at every 3rd position (Gly-X-Y) and X and Y are mostly proline and hydroxyproline. According to Ramachandran

This is an open-access article distributed under the terms of the Creative Commons Attribution-Non Commercial-Share Alike 4.0 License, which allows others to remix, tweak, and build upon the work non-commercially, as long as the author is credited and the new creations are licensed under the identical terms.

©2020 Published by Scientific Scholar on behalf of Journal of Global Oral Health

and Karta, each triplet consists of two hydrogen molecules.^[5] While Rich and Crick, North and Coworker later described the structure of collagen as that having only one hydrogen bond/triplet.^[7] The content of 4-hydroxyproline forms the intramolecular hydrogen bonds and contributes to the stability of the collagen triple helix.^[3] The collagen molecule has a stagger of 65 nm between adjacent rows. The length of the stagger is quarter of the length of the molecule and this quarter stagger arrangement gives the 65 nm banding characteristic under the electron microscope.^[8] A small amount of carbohydrate, in the form of glucose-galactose disaccharide, is also present in this triple helical structure, and the amount per tropocollagen molecule depends on the type of collagen. The structure of collagen also has non-collagenous domains which are important for the structural stability of the molecule. These domains are seen flanking the central part of the molecule and are called -C and -N terminals of the molecule. The -C terminal is involved in initiation of the polypeptide chain formation while the -N terminal is associated with the regulation of the fibril diameter [Figure 1].^[9] The tropocollagen molecules in collagen have a molecular weight of 300,000 and are of 260 nm in length. The three polypeptide chains coiled together have a pitch of 0.858 nm. The individual α -helices, on the other hand, have a pitch of 0.54 nm.^[8]

SYNTHESIS AND DEGRADATION

Collagen is not synthesized from fibroblasts alone but by various other cells such as cementoblasts, odontoblasts, chondroblasts, osteoblasts, muscle cells, epithelial cells, endothelial cells and Schwann cells.^[10,11] Although these cells secrete collagen in the same manner as that of fibroblasts, the types of collagen they secrete vary.

The formation of collagen starts in the nucleus where various exons of a gene are joined to form messenger RNAs (mRNAs) of different types of collagen.^[6] The mRNA is transported to the cytoplasm from the nucleus and is translated at the ribosomes of the rough endoplasmic

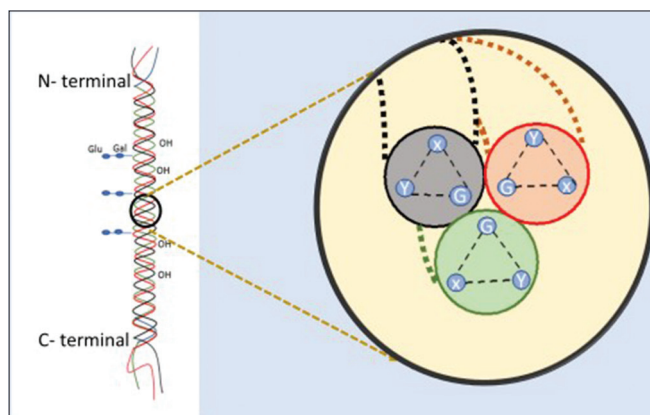


Figure 1: Triple helical structure of collagen.

reticulum (RER), leading to the formation of 3- α -polypeptide chains. These chains move into the cisternae of the RER where hydroxylation of the proline and lysine residues occurs. This step occurs under the influence of Vitamin C and the enzyme prolyl hydroxylase and lysyl hydroxylase. In addition, in the RER, galactosyltransferase brings about glycosylation of some of the hydroxylysine residues. The triple helix chains are joined by disulfide bonds in the presence of disulfide isomerase, which help to keep the chains properly aligned to each other, following which a molecule called procollagen is formed. The length of procollagen is many times longer than the final product (collagen). Twisting of this large molecule occurs before it passes into the golgi complex. Within the Golgi complex, a final glycosylation takes place by the addition of glucose at the O-linked galactose residues. This molecule then moves out of the trans face of the Golgi complex by being contained within secretory granules.^[10,11]

Extracellularly, the -C terminal and part of -N terminal of this helical structure are cleaved by -C and -N proteinases, respectively, leading to the formation of tropocollagen – a 5-unit quarter stagger microfibril. The remaining part of the N-terminal is cleaved by procollagen peptidase. In this way, the large collagen molecule is trimmed. The stabilizing of the collagen molecule occurs through the cross-linking of the molecule by oxidation of the lysine and hydroxylysine residues by lysyl oxidase [Figure 2].^[10,11]

In normal tissues along with the synthesis of collagen, its degradation, followed by replacement with new fibers, is also necessary for constant remodeling of the connective tissue. The degradation is necessary in physiological processes such as development and tissue repair and pathological processes such as tumorigenesis and metastasis. Collagen is cleaved in two locations, intracellular and extracellular. Intracellular degradation is the most important mechanism for remodeling of the connective tissue. It occurs in the following manner: (a) Recognition of the fibrils by binding to fibroblast integrin receptors, (b) partial digestion into smaller fibrils, (c) formation of phagolysosome, and (d) digestion of the fibrils by lysosomal enzymes [Figure 2].^[11] Extracellular degradation occurs through the secretion of enzymes, namely, the matrix metalloproteinases (MMPs) by the fibroblasts, inflammatory cells and tumor cells.^[11,12]

The inhibition of degradation through collagenases and other MMPs is brought about by tissue inhibitors of metalloproteinases (TIMPs), which bind to the active site of these enzymes to inhibit them.^[2,11] The different types of MMPs secreted cleave selective types of collagens and are denoted by different names.^[12] These are collagenases, gelatinases, stromelysin, metalloelastases, matrilysin and MT-MMPs which are specified in Table 1.^[2,10,11,13]

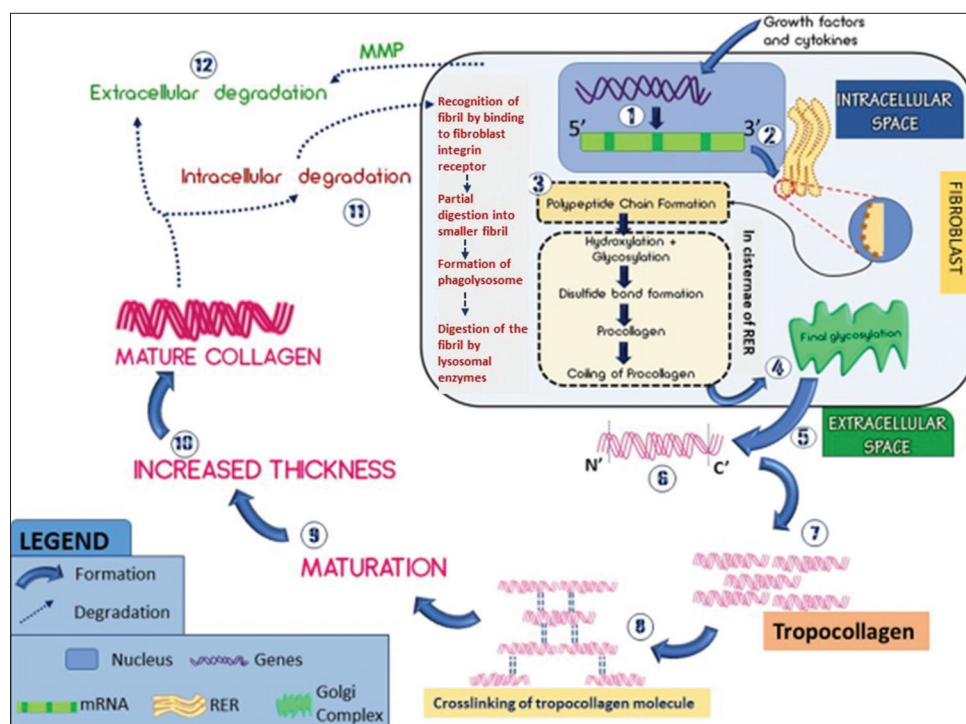


Figure 2: Synthesis and Degradation of Collagen. Synthesis: (1) Genetic transcription initiated by various growth factors and cytokines; (2) mRNA formed by joining of exons of a gene followed by splicing of introns of a gene; (3) polypeptide chain formation on ribosomes and hydroxylation of lysine and proline residues (prolyl hydroxylase and lysyl hydroxylase), glycosylation (galactosyltransferase) of lysine residues and disulfide bond formation (disulfide isomerase) between the chains, leading to the formation of procollagen in the cisternae of the rough endoplasmic reticulum; (4) final glycosylation of the O-linked galactose residues; (5) moves extracellularly; (6) cleavage of the -C and part of -N terminals by proteinases; (7) 5-unit quarter stagger fibril formed called tropocollagen; (8) cross-linking of the fibrils at lysine and hydroxylysine residues. (9 and 10) Maturation of collagen. Degradation: (11) Intracellular degradation by ingestion of collagen fibrils, (12) extracellular degradation by secretion of matrix metalloproteinases by the cells such as fibroblasts and leukocytes.

Table 1: Enzymes for collagen degradation.

Enzyme	MMP type	Collagen degradation
Collagenase	MMP 1	I, II, III, VII, VIII, X
	MMP 8	I, III
	MMP 13	I, II, III, V, IV, IX, X, XI
Gelatinase	MMP 2, MMP 9	IV, V, VII, X, XI
		Stromeolysin
Stromeolysin	MMP 3	IV
	MMP 10	X, XI, Laminin
	MMP 11	Procollagen I, II, III Fibronectin Elastin
Matelloelastase	MMP 12	Elastin collagen
Matrilysin	MMP 7	Elastin
Membrane type MMP	MMP 14	IV, Fibronectin, Laminin

MMP: Matrix metalloproteinase

TYPES OF COLLAGEN

The various types of collagen are mentioned in Table 2, along with their function and distribution in different

orodental tissues.^[11] They can be differentiated based on size, distribution, function, and structure. Based on these findings, they can be classified as fibril associated collagens with interrupted triple helices, microfibril forming, anchoring fibril, network forming, multiplexin, transmembrane and miscellaneous.^[11]

STAINS FOR COLLAGEN

Hematoxylin and eosin is the routinely used stain in histopathology and is generally sufficient to make visible a number of components of a tissue under the light microscope. However, in terms of evaluating collagen, sometimes, this stain may fall short in helping the clinician differentiate collagen fibers from other fibers such as keratin and muscle. Hence, in these instances, various special stains can be used which specifically stain collagen, as given in Table 3. These stains are differentiated based on color to aid in better understanding. Van Geison imparts a red color to collagen, PAS, Weigert's resorcin-fuchsin and Wilder's modification of Bielschowsky's stain, all stain collagens in various shades of pink. Masson's trichrome, Lillie's modification of Masson's

Table 2: Types of collagen.

Type of collagen	Special features	Distribution in orodental tissues
I	Most abundant	Bone, dentin, cementum, tendon, and ligaments
II	Heterofibril with IX and XI	Cartilage
III	Most in elastic tissues	Pulp, blood vessels, lymphoid tissue, and embryonic tissue
IV	Interacts with laminin, integrin, nidogen, and Type IV collagen	Basal lamina
V	1. Forms core of Type I 2. Binds to DNA, heparin sulfate, heparin, thrombospondin, and insulin	Basal lamina, dentin, skin blood vessels, periodontal ligament
VI	Disulfide bonds	Skin, ligament skin
VII	Dimers in anchoring plaques	Epithelium
VIII		Endothelium
IX	Associated with cartilage glycosaminoglycans	Cartilage
XI	Core of Type II	Cartilage
XII		Abundant in connective tissue
XIII	Transmembrane domain and collagenous domain	Cell surface, focal adhesions, epidermis
XIV		Abundant in connective tissue
XV	Antiangiogenic factors	Epithelium and endothelium
XVI	Interruptions present	Perineural, endothelium, epithelial basal lamina, muscle
XVII	Hydrophobic transmembrane	Hemidesmosome
XVIII	Antiangiogenic factors	Epithelium and endothelium
XIX		Perineural, endothelium, epithelial. Basal lamina, muscle
XX		Tendon, cartilage
XXI		Abundant in vascular channels
XXII		Myotendinous junction Articular disc Synovial joints
XXIV	Intervertebral fibrillar collagen	Bone
XXVI	Disulfide form trimers at N-terminal	Peripheral nerves
XXVII	Triple helix imperfections	Cartilage
XXVIII	Disulfide form trimers at N-terminal	Peripheral nerves

Table 3: Identification of collagen.

Staining technique	Color
a. Light microscopy	
Hematoxylin and eosin	Pink
Lilies modification of Masson's trichrome	Blue to blue-green
Weigert's resorcin-fuchsin	Red-pink
Goldner's trichrome	Green
Wilder's modification of Bielschowsky's method	Pale pink
b. Polarizing microscopy	
Picrosirius red	Yellow-red birefringence

trichrome, Goldner's trichrome, Martius scarlet blue and Gomori's trichrome stain collagen blue or green.

Apart from light microscopy, polarizing microscopy is also used to identify and analyze collagen. Electron microscopy provides information on the size, height and shape of the fibrils. Transmission microscopy helps to study the protein and peptide in collagen.^[2,14]

COLLAGEN IN NORMAL TISSUES

The maxillofacial region is formed by a number of hard and soft tissues where the collagens form a principal component. These are basically bone, connective tissue, muscles, tendons, cartilage and oral mucosa. Among the dental tissues excluding enamel, the collagens are found in dentin, cementum, pulp and periodontal ligament (PDL).

BONE, TENDON, CARTILAGE AND MUSCLE

Bone is made of 22–25% organic component, of which 94–98% is Type I collagen and non-collagen proteins, while 2–5% are cells. The combination of hard mineral and flexible collagen makes bone harder than cartilage but lacks brittleness.^[10] Cartilage is made up of mostly Type II collagen. In tendon, ligaments, and cartilage, collagen is present in the form of elongated fibrils. In tendons, collagens constitute 75% of the dry tendon weight and functions chiefly to withstand and transmit large forces between muscle and bone. Tendons are chiefly made up of Type I collagen. In muscle tissue, the predominant fibers are the muscle fibers, while collagen fibers comprise only 1–2% of it.^[10,11]

DENTIN

The mature dentin is made up of 70% inorganic material, 20% organic material, and 10% water by weight. About 20% of the organic material is collagen, mainly of Type I. Small amounts of Type III and Type V collagen and some non-collagenous matrix proteins are also found in dentin. Collagen acts as a scaffold for the mineral components of dentin.^[15,16]

PULP

The pulp is a loose connective tissue that is highly vascularized and innervated. It is made up of Type I and III collagen. They are present in the extracellular matrix (ECM) along with the ground substance. As age increases, the collagen content of the pulp increases, leading to fibrosis.^[15,17]

CEMENTUM

The cementum is made up of 45–50% hydroxyapatite by weight and 50–55% organic material, proteins, and water. The major type of collagen to form the bulk of the organic component of the cementum is Type I along with other types, namely, Type III, XII, V, VI and XIV which are found in smaller proportions. The amino acid analysis reveals that the collagen of dentin, alveolar bone, and cementum in human teeth is similar.^[18] Type III, which is a less cross-linked collagen, is found in high concentrations during development, repair, and regeneration of mineralized tissues like cementum.^[19]

PDL

The major part of the collagen content of the PDL is formed by collagen Type I (70%). Other collagens found in large proportions, are collagen II, III and XII. Small amounts of Type V and Type VI collagens and trace of Type IV and Type VII collagen are also found in the ligament.^[11,18] The vast majority of collagen fibrils in the PDL are arranged in definite and distinct fiber bundles and these are termed as principal fibers. The PDL has also the capacity to adapt to functional changes. When functional demand increases, the width of PDL increases and so does the fiber bundles thickness. Collagen in PDL is not mineralized, but its Sharpey's fibers are partly mineralized, which are embedded in the bone and cementum.^[11,20]

TOOTH ERUPTION

PDL fibroblasts contract and transmit a contractile force to the extracellular environment; this permits summation of contractile forces. They also exhibit fibronexuses by which such forces can be transmitted to the collagen fiber bundles. Although the *in vitro* observations conclude the

myofibroblastic nature of the fibroblast and the existence of fibronexus, *in vivo* findings do not support the migratory nature or features of myofibroblast and the existence of fibronexus between fibroblast and fibers. Therefore, these cells would not be able to transmit a tractional force required to pull the tooth in eruption.^[11]

ORAL MUCOUS MEMBRANE

The surface of the oral cavity is bounded by mucous membrane or oral mucosa. The two main tissue components of the oral mucosa are stratified squamous epithelium, called the oral epithelium, and an underlying connective tissue layer called the lamina propria. Lamina propria consists of ground substance, collagen fibers, and different cells. Collagen in the lamina propria is primarily Type I and Type III.^[11,18]

The interface between the connective tissue and the epithelium in light microscopy appears thick and it includes the reticular fibers. It is a 1–4 µm wide zone. It consists of both lamina and the fibers.^[18] The basal lamina runs parallel to the basal cell membrane of the epithelial cells and at the ultrastructural level consists of three zones: The lamina lucida, lamina densa, and lamina fibroreticularis. The lamina densa consists essentially of a network of polymers of Type IV collagen and laminins. The lamina lucida essentially contains proteins that attach the cell to the basal lamina, that is, the interacting portions of hemidesmosome-associated membrane proteins (collagen XVII, integrins) and laminin-332. Anchoring fibrils, consisting of collagen Type VII, insert into the lamina densa and form a flexible attachment between the basal lamina and subjacent connective tissue.^[11]

SKIN

Skin is majorly composed of Type I collagen which accounts for 70% followed by Type III collagen which accounts for 10%. Trace amounts of collagen Types IV, V, VI and VII are also found.^[10,14] Collagen maintains firmness and elasticity of skin. With aging, Type III collagen synthesis reduces resulting in changes in skin tension, elasticity and healing.^[10]

Apart from their presence in the normal tissues in the maxillofacial region, the collagens also play a key role in different physiologic mechanisms like wound healing.

WOUND HEALING

During the healing of wounds on skin or in the oral cavity, around the 3rd day fibroblasts invade the tissue. These cells originate either from undamaged fibroblasts at the periphery of the wound or from undifferentiated

connective tissue cells and around the 5th day collagen is formed which causes contraction of the wound and an increase in the tensile strength of the wound.^[11] The wound healing in the oral cavity generally heals without scarring but in some cases could include fibrosis.^[21] This scarless healing seen in oral cavity is also seen in fetal wounds. Authors have attributed this scarless healing to ECM content of fetal wounds. One of the ECM contents, which was considered as a contributing factor toward scarless healing, is the type of collagen. Fetal wounds have more of Type III collagen fibers, which help in keeping the wound less rigid and also allow better cell migration and regeneration. In addition, the ECM of fetal wounds has fibroblasts that have a faster rate of collagen secretion, wherein as they proliferate they simultaneously secrete collagen.^[22] All these factors could also contribute to scarless healing in the oral cavity. The most common wound healing occurring in the oral cavity is tooth extraction wound. Here, the wound heals primarily by the invasion of the clot tissue by osteogenic cells, leading to the formation of bone while the overlying epithelium heals like any other cutaneous wounds but without scar formation.^[11]

CONCLUSION

As collagen is an integral part of the oral cavity, both in its soft tissue and in its hard tissue, it is very important to know about its structure, function and distribution. Any aberration in its formation and its structure can alter its function which ultimately leads to various pathologies in the body and the oral cavity.

Acknowledgment

- Dr. J V Tupkari (Ex-Dean, Ex-Prof and Head of Department of Oral Pathology and Microbiology, Government Dental College and Hospital, Mumbai)
- Dr. Vivek Pakhmode (Dean, Government Dental College and Hospital, Mumbai)
- Dr. Sanpreet Singh (1st year Post Graduate Student, Department of Oral Pathology and Microbiology, Government Dental College and Hospital, Mumbai).

Declaration of patient consent

Not required as there are no patients in the study.

Financial support and sponsorship

Nil.

Conflicts of interest

There are no conflicts of interest.

REFERENCES

1. Kadler KE, Baldock C, Bella J, Boot-Handford RP. Collagens at a glance. *J Cell Sci* 2007;120:1955-8.
2. Deshmukh SN, Dive AM, Moharil R, Munde P. Enigmatic insight into collagen. *J Oral Maxillofac Pathol* 2016;20:276-83.
3. Astbury WT, Bell FO. Molecular structure of the collagen fibers. *Nature* 1940;145:421-2.
4. Pauling L, Corey RB. Stable configurations of polypeptide chains. *Proc R Soc Lond B Biol Sci* 1953;141:21-33.
5. Ramachandran GN, Kartha G. Structure of collagen. *Nature* 1954;174:269-70.
6. Gelse K, Pöschl E, Aigner T. Collagens--structure, function, and biosynthesis. *Adv Drug Deliv Rev* 2003;55:1531-46.
7. Rich A, Crick FH. The structure of collagen. *Nature* 1955;176:915-6.
8. Williams R, Elliott JC. *Basic and Applied Dental Biochemistry*. 2nd ed. Edinburgh, London, New York: Churchill Livingstone; 1989. p. 49-50.
9. Bateman JF, Lemande SR, Ramshaw JA. In: Comper WD, editor. *Extracellular Matrix*. Melbourne: Harwood Academic Press; 1996. p. 22-67.
10. Sandhu SV, Gupta S, Bansal H, Singla K. Collagen in health and disease. *J Orofac Res* 2012;2:153-9.
11. Nanci A. *Ten Cate's Oral Histology Development, Structure, and Function*. 8th ed. India: Elsevier; 2013. p. 205-16.
12. Ricard-Blum S. The collagen family. *Cold Spring Harb Perspect Biol* 2011;3:a004978.
13. Reynolds JJ. Collagenases and tissue inhibitors of metalloproteinases: a functional balance in tissue degradation. *Oral Dis* 1996;2:70-6.
14. Suvarna SK, Christofer L, Bancroft JD. *Theory and Practice of Histological Techniques*. 8th ed. China: Elsevier; 2019.
15. Linde A. Session II: Cells and extracellular matrices of the dental pulp-C.T. Hanks, Chairman: The extracellular matrix of the dental pulp and dentin. *J Dent Res* 1985;64:523-29.
16. Goldberg M, Kulkarni AB, Young M, Boskey A. Dentin: Structure, composition and mineralization. *Front Biosci (Elite Ed)* 2011;3:711-35.
17. Kabartai F, Hoffaman T, Hanning C. Cellular reduction and pulp fibrosis can be related not only to aging process but also to a physiologic static compression. *Dent Hypothesis* 2017;8:42-5.
18. Kumar GS. *Orban's Oral Histology and Embryology*. 13th ed. India: Elsevier; 2011. p. 72-6.
19. Giansanti JS. The pattern and width of the collagen bundles in bone and cementum. *Oral Surg Oral Med Oral Pathol* 1970;30:508-14.
20. Newman MG, Takei HH, Carranza FA. *Carranza's Clinical Periodontology*. 11th ed. New Delhi: Elsevier; 2012.
21. Politis C, Schoenaers J, Jacobs R, Agbaje JO. Wound healing problems in the mouth. *Front Physiol* 2016;7:507.
22. Larson BJ, Longaker MT, Lorenz HP. Scarless fetal wound healing: A basic science review. *Plast Reconstr Surg* 2010;126:1172-80.

How to cite this article: D'souza Z, Chettiankandy TJ, Ahire MS, ThakurA, Sonawane SG, Sinha A. Collagen – structure, function and distribution in orodental tissues. *J Global Oral Health* 2019;2(2):134-9.