

Research Article

## Comparison of the rate of maxillary canine retraction with or without modified corticotomy facilitated orthodontic treatment

M. Kokila<sup>1</sup>, Vinaya S. Pai<sup>1</sup>, Siri Krishna<sup>1</sup>, Gautham Kalladka<sup>1</sup>, Shreyas Rajaram<sup>1</sup>, Shivparasad Goankar<sup>1</sup>

<sup>1</sup>Department of Orthodontics and Dentofacial Orthopaedics, Bangalore Institute of Dental Sciences and Hospital, Bangalore, Karnataka, India.



**\*Corresponding author:**

Dr. M. Kokila,  
Department of Orthodontics  
and Dentofacial Orthopaedics,  
Bangalore Institute of Dental  
Sciences and Hospital,  
Bangalore, Karnataka, India.

mailsamykokila@gmail.com

Received : 30 September 2020

Accepted : 22 November 2020

Published : 25 June 2021

**DOI**

10.25259/JGOH\_56\_2020

**Quick Response Code:**



### ABSTRACT

**Objectives:** The aim of the study was to evaluate and compare the rate of maxillary canine retraction in cases with modified corticotomy versus without modified corticotomy. Clinical interventional study. Split mouth design was used.

**Materials and Methods:** A sample size of ten patients and 20 sites were selected within the age group of 18–35 years following all criteria of the study. Before orthodontic leveling and alignment, upper first premolar extraction was carried out under local anesthesia. Pre-treatment OPG and IOPA were taken in relation to the maxillary canine and maxillary second premolar teeth. One extraction side was considered as the experimental site and contralateral side as control. Leveling and alignment were started with wire sequence. After modified corticotomy procedure, the canine retraction was started with 8 mm NiTi closed coil spring. The amount of tooth movement was recorded with the help of a Digital Vernier Caliper at an interval of 1 month till the completion of canine retraction.

**Results:** Paired *t*-test showed higher mean velocity of tooth movement in modified corticotomy side ( $1.07 \pm 0.25$ ) as compared to the conventional side ( $0.91 \pm 0.24$ ), ( $P < 0.001$ ).

**Conclusion:** The modified corticotomy technique serves as an effective treatment modality for adults seeking orthodontic treatment with increased rate of orthodontic canine retraction.

**Keywords:** Canine retraction, Modified corticotomy, NiTi closed coil spring, Rapid tooth movement

### INTRODUCTION

The goal of orthodontic treatment is to improve the patient's life by enhancing the dentofacial function and esthetics.<sup>[1]</sup> The drawbacks of prolonged orthodontic treatment are bone loss, root resorption, gingival recession, root dehiscence, fenestration, and decreased patient compliance.<sup>[2]</sup> Adults may show decreased rate of tooth movement due to decreased blood supply and cancellous bone volume.<sup>[3]</sup>

In recent era, patients desire reduced treatment time with favorable outcomes. To accomplish that, various methods have been implemented to accelerate the tooth movement by increasing the rate of bone turnover and decreasing the bone density leading to a regional acceleratory phenomenon (RAP).<sup>[2]</sup>

This is an open-access article distributed under the terms of the Creative Commons Attribution-Non Commercial-Share Alike 4.0 License, which allows others to remix, tweak, and build upon the work non-commercially, as long as the author is credited and the new creations are licensed under the identical terms.

©2021 Published by Scientific Scholar on behalf of Journal of Global Oral Health

The term “regional” refers to the demineralization of both the cut site and adjacent bone. The term “acceleratory” refers to an exaggerated or intensified bone response in cuts that extend to the marrow. For both normal and accelerated tooth movement, RAP may be an important prodromal action to effective tooth movement. It is postulated that osteoclast and osteoblast cell populations shift in number, resulting in an osteopenic effect.<sup>[4]</sup>

Many surgical procedures are combined with conventional orthodontics for reducing the treatment period, and to reshape the alveolar arch.<sup>[5]</sup>

Corticotomy is defined as any intentional surgical injury to cortical bone.<sup>[1]</sup> The original technique of corticotomy was described by Kole in 1959, which was a combination of interdental corticotomies and supra-apical corticotomies,<sup>[5]</sup> to enable the mobility of bony segments.<sup>[2]</sup> According to him, the tooth embedded in a bony block of medullary bone serves as the handle by which bands of less dense medullary bone surrounding the teeth are moved block by block.<sup>[1]</sup>

Corticotomy is a surgical procedure in which bur holes are made through both the buccal and/or lingual cortical plates surrounding the tooth so that the tooth sits in a block of bone connected to other teeth and structures only through the medullary bone.<sup>[5]</sup>

Advantage of corticotomy is to accelerate tooth movement, and it has been proven successfully by many authors that bone can be augmented, thereby preventing periodontal defects, which might arise, as a result of thin alveolar bone.<sup>[6]</sup>

There are few possible risks of corticotomy procedure, such as periodontal damage and devitalization of the teeth and osseous segments because of inadequate blood supply.<sup>[1]</sup> High morbidity associated with the procedure, invasiveness of the procedure, post-operative pain, swelling, chances of infection, avascular necrosis, and low acceptance by the patient<sup>[6]</sup> has led to the modification of this technique.<sup>[1]</sup>

Modified corticotomy facilitated orthodontic treatment proposed by Germec *et al.* was a comparatively new treatment, which promised to shorten the treatment time with an oral surgical procedure. In this modified corticotomy technique, lingual supra-apical horizontal and lingual vertical cuts were not be performed. After bleeding control, the flap was repositioned and closed primarily.<sup>[5]</sup>

The aim of the present study was to compare and evaluate changes in the rate of maxillary canine retraction in cases with modified corticotomy versus without modified corticotomy.

## MATERIALS AND METHODS

This prospective study was conducted in the Department of Orthodontics and Dentofacial Orthopaedics, Bangalore Institute of Dental Sciences and Hospital, Rajiv Gandhi

University of Health Sciences, Bengaluru, Karnataka, with the Institutional (Bangalore Institute of Dental Sciences and Hospital) Ethical Committee approval and split mouth design was used for this study.

### Inclusion criteria

The following criteria were included in the study:

- Age range from 18 to 35 years
- Patients requiring extraction of maxillary first premolars
- Crowding  $\leq 3$  mm
- Healthy systemic condition
- Good oral hygiene.

### Exclusion criteria

The following criteria were excluded from the study:

- Alveolar bone loss
- Periodontal disease
- Diseases such as rheumatoid arthritis that require NSAIDS interfering with orthodontic tooth movement
- Previous history of orthodontic treatment.

A split mouth study technique was designed for the comparison of the rate of maxillary canine retraction with and without modified corticotomy. A sample size of ten patients and 20 sites were selected within the age group of 18–35 years following all criteria of the study.

After selection, the surgical procedure was explained to all the patients. A written informed consent was obtained from all the patients. All the patients were started with the routine orthodontic procedure. 0.022”X0.028” MBT Pre-adjusted edgewise brackets was used. Upper first premolar extraction was carried out before orthodontic leveling and alignment under local anesthesia. Pre-treatment orthopantomograph [Figure 1] and intraoral peri-apical radiograph [Figure 2] were taken using orthopantomogram and carestream E-speed film, respectively, in relation to the maxillary canine and maxillary second premolar teeth. Experimental site was selected based on the extraction space having more distance to be travelled by maxillary canine; so as to gain the benefit of proposed advantage of the technique.

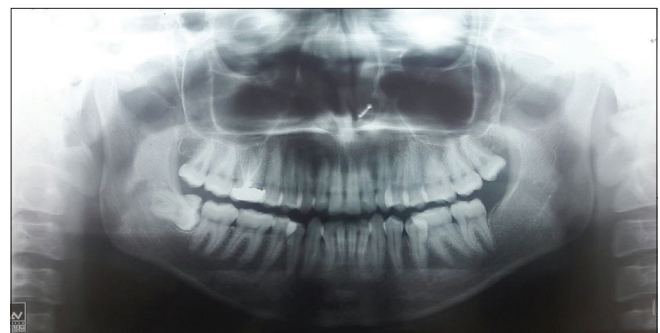

Figure 1: Pre-treatment orthopantomograph.

Leveling and alignment were done using 0.014”NITI, 0.018”NITI, 0.019”X0.025”NITI, and 0.019”X0.025”SS wire. Trans Palatal Arch and consolidation of the posterior segment were done to reinforce the anchorage. All the procedures were carried out by the same surgeon using standard surgical technique. Labial sulcular incision was made using Blade number.11 with BP handle under local anesthesia and a full thickness mucoperiosteal flap was elevated. The vertical guideline bur holes were performed on the buccal cortex, distal to canine, and mesial to second premolar, with a 0.5 mm diameter surgical bur using low speed micromotor straight handpiece. These bur holes extended through the cortical bone, just minimally penetrating into the spongiosa. These bur holes were connected using a chisel to reach the lingual cortical bone from labial side [Figure 3]. In this modified corticotomy technique, lingual supra-apical horizontal and lingual vertical cuts were not performed. Bleeding was controlled and after obtaining a clean surgical site, the flap was repositioned and sutured with nonresorbable 4-0 black silk suture material and was closed with a periopack.

As the time span between the surgery and tooth movement was critical, the canine retraction was started immediately after the surgical procedure. 0.019”X0.025”SS wire was used for retraction with 8 mm NiTi Closed coil springs [Figure 4]. Equal amount of orthodontic forces was applied bilaterally with the help of Dontrix gauge (150 g/side). A digital Vernier

caliper was used to record the amount of tooth movement [Figure 5]. The measurements were recorded from the cusp tip of canine to the mesial pit of the second premolar at an interval of 1 month till the completion of canine retraction. Intraoral periapical radiograph [Figure 6] in relation to the maxillary canine and maxillary second premolar teeth was obtained at the end of canine retraction to check for adverse effects such as periodontal damage, loss of vitality of the tooth, and root resorption on the experimental site. Following this, a comparison was done for the rate of canine movement between the experimental site and control site. Paired *t*-test was used to analysis the statistical difference between the conventional and modified corticotomy groups.

### Statistical analysis

Data were entered into Excel sheet and the analysis was performed using SPSS version 22 (IBM, CHICAGO). All the data were subjected to statistical analysis using paired *t*-test including mean and standard deviation to compare the

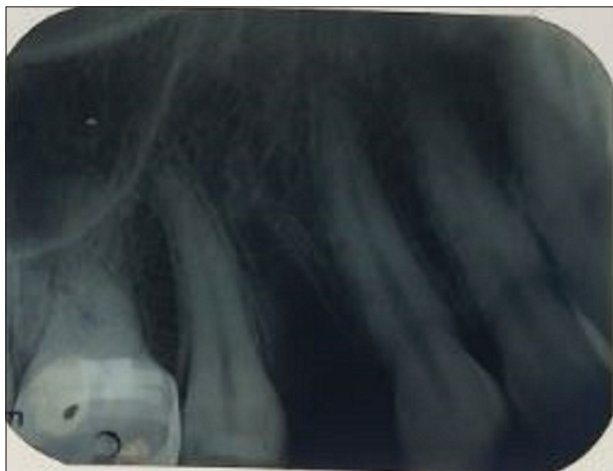


Figure 2: Pre-treatment intraoral periapical radiograph.

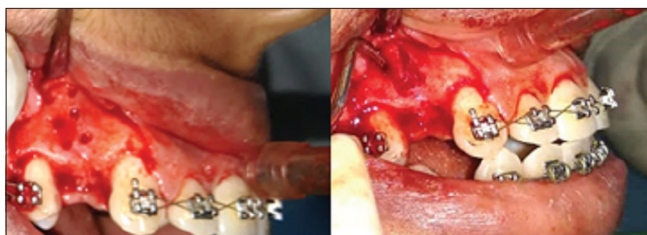

Figure 3: Defined segment of cortical bone distal to canine.

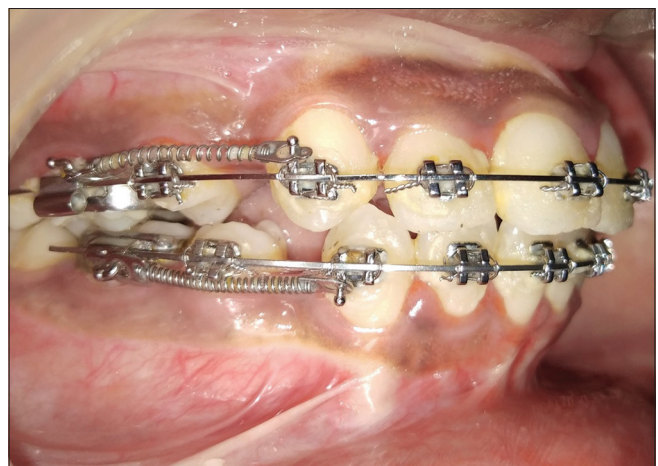


Figure 4: Canine retraction using closed NiTi coil spring.

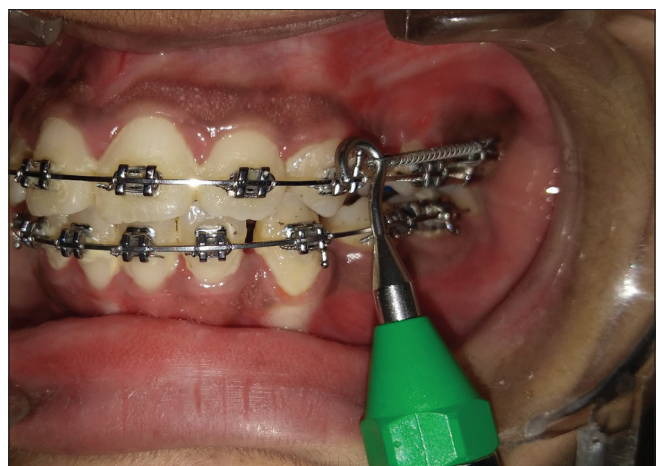
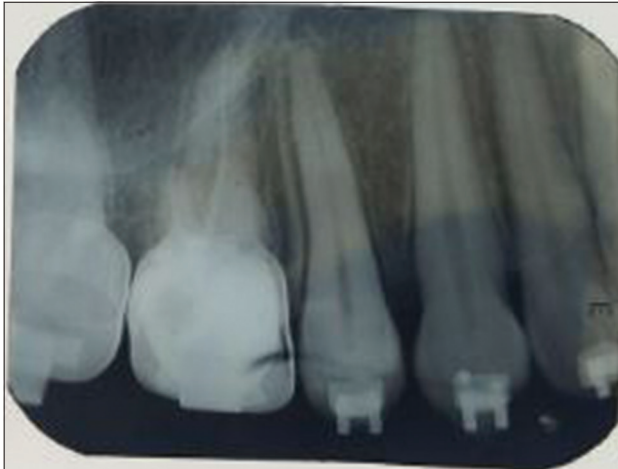
Figure 5: Measurement of force with dontrix gauge.





**Figure 6:** Post-treatment intraoral periapical radiograph.

velocity or rate of tooth movement (mm/month) between the modified corticotomy and conventional groups. *P*-value was set as at  $\leq 0.05$  (95% confidence interval).

**RESULTS**

The present study was carried out in the Department of Orthodontics and Dentofacial Orthopaedics, Bangalore Institute of Dental Sciences and Hospital, Bengaluru, to compare the rate of maxillary canine movement with and without modified corticotomy facilitated orthodontic treatment. The study comprised a total sample of ten patients within the age group of 18–35 years, with 20 sites being assessed for the rate of maxillary canine movement.

The extraction space having more distance to be travelled by maxillary canine was selected as an experimental site, so as to gain the benefit of proposed advantage of this technique. After the corticotomy procedure was performed, the baseline readings in millimeters were recorded bilaterally with the help of Vernier Calipers from the cuspal tip of the canine to the mesial pit of the second premolar. The space present on both the sites was recorded for both the groups at baseline as well as at intervals of 1 month till the end of space closure.

Graph 1 depicts the evaluation of velocity or the rate of tooth movement (mm/month) in the two groups in the whole assessment time. The velocity or rate of tooth movement (mm/month) between the modified corticotomy and conventional sites showed that the rate of tooth movement in all ten patients was higher in the modified corticotomy side as compared to the conventional side.

[Table 1] depicts the mean velocity or rate tooth movement (mm/month) which was recorded in the two groups using paired *t*-test which showed that higher mean velocity was seen in modified corticotomy group ( $1.07 \pm 0.25$ ) as compared to the conventional group ( $0.91 \pm 0.24$ ). Paired

**Table 1:** Statistical analysis of velocity of tooth movement (mm/month) between the two groups using paired *t*-test.

Group	<i>n</i>	Mean	SD	Mean difference	<i>t</i>	<i>P</i> -value
Modified corticotomy	10	1.07	0.25	0.161	6.922	<0.001*
Conventional	10	0.91	0.24			

\*Statistically significant difference; SD: Standard deviation. Paired *t*-test used since this is quantitative data and has normal distribution

*t*-test measurement was found to be statistically significant ( $P < 0.001$ ), which indicates higher velocity of tooth movement in the modified corticotomy sides as compared to conventional sides.

This shows that the modified corticotomy group had a higher mean velocity of tooth movement as compared to the conventional group.

The result of the study of comparison of rate of maxillary canine retraction with and without modified corticotomy shows that velocity or rate of tooth movement is higher in modified corticotomy group when compared to the conventional group. Modified corticotomy technique serves as an effective alternative to accelerate orthodontic tooth movement, without adverse effects such as periodontal damage, root resorption, and the loss of vitality of the tooth by clinical and radiographic examination

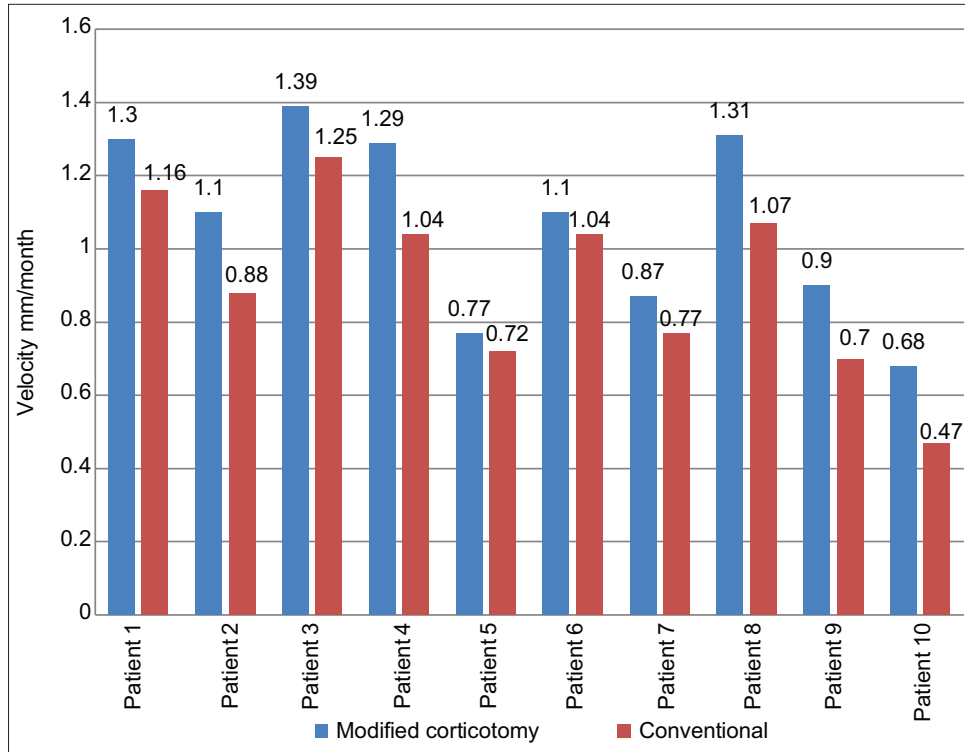
**DISCUSSION**

Bone loss, root resorption, gingival recession, root dehiscence, fenestration, and decreased patient compliance are the drawbacks of prolonged orthodontic treatment.<sup>[2]</sup> In recent era, the patients desire to have a reduced treatment time with favorable outcomes.<sup>[2]</sup> Many surgical procedures are combined with conventional orthodontics that are used for reducing the treatment period, fastening the tooth movement, to facilitate difficult tooth movements, and to reshape the alveolar arch.<sup>[5]</sup>

Methods to accelerate orthodontic tooth movement can be summarized into three major groups:

1. Biologic approaches or local administration of chemicals
2. Physical or mechanical stimulation of the alveolar bone, such as the use of lasers, piezoelectric, direct electric current, or magnets
3. Surgical approaches including interseptal alveolar surgery, micro-osteoperforations, Piezocision, and corticotomies.<sup>[6]</sup>

One such procedure is orthodontic treatment combined with corticotomy which results in shorter retraction time and reduced orthodontic treatment duration by increasing the



**Graph 1:** Comparison of the mean velocity of tooth movement (mm/month) in the two groups for each patient.

rate of tooth movement.<sup>[1]</sup> There are a few possible risks of corticotomy procedure that has led to the modification of this technique.<sup>[1]</sup> Modified corticotomy facilitated orthodontic treatment proposed by Germec *et al.* is a comparatively new treatment, which promises to shorten the treatment time with an oral surgical procedure.<sup>[3]</sup>

Suryavanshi *et al.* conducted a study<sup>[5]</sup> for comparison of the rate of maxillary canine movement with or without modified corticotomy facilitated orthodontic treatment. A split mouth study design was carried out and total sample size of ten patients within the age group 18–35 years requiring maxillary first premolar extractions, undergoing fixed orthodontic treatment with preadjusted edgewise appliance. In this modified corticotomy technique, lingual supra-apical horizontal and lingual vertical cuts were not be performed. Higher mean velocity or rate of canine movement was observed in the modified corticotomy side ( $1.02 \pm 0.10$ ) as compared to conventional side ( $0.81 \pm 0.07$ ). The difference in mean velocity between the two groups was found to be statistically significant ( $P < 0.001$ ). The study concluded that modified corticotomy technique serves as an effective alternative to accelerate orthodontic tooth movement, without adverse effects such as periodontal damage, root resorption, and the vitality of the tooth by clinical and radiographic examination. Similarly, in our study, our results showed higher mean velocity or rate of tooth movement in modified corticotomy  $1.07 \pm 0.25$  mm/month when

compared to the conventional side  $0.91 \pm 0.24$  mm/month and it was found to be statistically significant ( $P < 0.001$ ).

Aboul-Ela *et al.* conducted a study<sup>[1]</sup> to clinically evaluate miniscrew implant-supported maxillary canine retraction with corticotomy-facilitated orthodontics. Using miniscrews as anchorage, canine retraction was initiated through closed nickel titanium coil springs applying 150 g of force per side. It was seen that the average daily rate of canine retraction was significantly higher on the corticotomy than the control side by 2 times during the first 2 months after the corticotomy surgery. On the other hand, during the 3<sup>rd</sup> and 4<sup>th</sup> months, this mean monthly rate, though still higher on the corticotomy side than the control side, declined to only 1.6 times higher in the 3<sup>rd</sup> month and 1.06 times higher by the end of the 4<sup>th</sup> month. The study concluded that rate of canine retraction was significantly higher on the corticotomy than the control side. In contrast, in our study transpalatal arch was used as an anchorage reinforcement instead of miniscrews. The mean velocity or rate of tooth movement which was recorded in the two groups showed higher velocity in the modified corticotomy group with the mean value of  $1.07 \pm 0.25$  mm/month as compared to the conventional group with mean value of  $0.91 \pm 0.24$  mm/month.

Jahanbakhshi *et al.* conducted a study<sup>[7]</sup> to evaluate the effect of buccal corticotomy in accelerating maxillary canine retraction. Canine retraction was performed by the

use of friction – less mechanics with simple vertical loop. The velocity of space closure was calculated to evaluate the effect of this technique in accelerating orthodontic tooth movement. The rate of canine retraction was significantly higher on the corticotomy side (1.8 mm/month) than the control side (1.1 mm/month), respectively ( $P < 0.001$ ). The authors concluded that corticotomy accelerates the rate of orthodontic tooth movement compared to conventional orthodontics and it is significant in early stages after surgical procedure. Our study was done in accordance with the above-mentioned study. The canine retraction was performed using NiTi closed coil spring in contrast to the above study which was done using vertical loops. In our study, the results showed that average velocity of canine retraction was significantly higher in the modified corticotomy  $1.07 \pm 0.25$  mm/month when compared to the conventional group  $0.91 \pm 0.24$  mm/month, respectively ( $P < 0.001$ ). Hence, we concluded that the rate of canine movement in corticotomy group was faster than the conventional group which showed similarity with the above-mentioned study.

### Limitations

According to our study, we found that there is significant difference between the modified corticotomy side and conventional side, showing that there is increase in velocity of tooth movement in the modified corticotomy. This result has to be further corroborated using larger sample size to obtain a characteristic validation with respect to rate of tooth movement in the modified corticotomy side and the en-masse retraction should also be evaluated to assess the complete treatment duration.

### CONCLUSION

The average orthodontic treatment time with extraction therapy is 31 months. One of the main disadvantages of orthodontic treatment is time. Unfortunately, many potential orthodontic patients jeopardize their dental health and decline treatment, due to the long treatment time and further multitude of appointments which are required. Furthermore, lengthy orthodontic treatment time has been linked to an increased risk of root resorption, gingival inflammation, decalcification, and dental caries. Corticotomy is a surgical procedure which accelerates the tooth movement and reduces orthodontic treatment duration. There are a few possible risks of corticotomy procedure that has led to the modification of this technique. Modified corticotomy facilitated orthodontic treatment was a comparatively new treatment, which promised to shorten the treatment time with an oral surgical procedure.

The result of the study of comparison of rate of maxillary canine retraction with and without modified corticotomy

showed that the higher mean velocity in modified corticotomy side  $1.07 \pm 0.25$  mm/month when compared to conventional side  $0.91 \pm 0.24$  mm/month, respectively ( $P < 0.001$ ). To the best of our knowledge, the results suggested that the modified corticotomy technique serves as an effective treatment modality for adults seeking orthodontic treatment with increased rate of orthodontic canine retraction. It is probably a useful adjunct to shorten the treatment time without any adverse effects such as periodontal damage, root resorption, and the loss of vitality of the tooth.

### Declaration of patient consent

The authors certify that they have obtained all appropriate patient consent.

### Financial support and sponsorship

Nil.

### Conflicts of interest

There are no conflicts of interest.

### REFERENCES

1. Aboul-Ela SM, El-Beialy AR, Fawzy El-Sayed KM, Selim EM, El-Mangoury NH, *et al.* Miniscrew implant-supported maxillary canine retraction with and without corticotomy facilitated orthodontics. *Am J Orthod Dentofacial Orthop* 2011;139:252-9.
2. Sakthi SV, Vikraman B, Shobana VR, Iyer SK, Krishnaswamy NR. Corticotomy-assisted retraction: An outcome assessment. *Indian J Dent Res* 2014;25:748-54.
3. Lee JK, Chung KR, Baek SH. Treatment outcomes of orthodontic treatment, corticotomy-assisted orthodontic treatment, and anterior segmental osteotomy for bimaxillary dentoalveolar protrusion. *Plast Reconstr Surg* 2007;120:1027-36.
4. Lee W, Karapetyan G, Moats R, Yamashita DD, Moon HB, Ferguson DJ, *et al.* Corticotomy-/osteotomy-assisted tooth movement microCTs differ. *J Dent Res* 2008;87:861-5.
5. Suryavanshi HN, Das VR, Deshmukh A, Rai R, Vora M. Comparison of rate of maxillary canine movement with or without modified corticotomy facilitated orthodontic treatment: A prospective clinical trial. *APOS Trends Orthod* 2015;5:138-43.
6. Sheneva S, Nayak US, Bhaskar V, Nayak A. Accelerated orthodontics-a review. *Int J Sci Stud* 2014;1:35-9.
7. Jahanbakhshi MR, Motamedi AM, Feizbakhsh M, Mogharehabet A. The effect of buccal corticotomy on accelerating orthodontic tooth movement of maxillary canine. *Dent Res J* 2016;13:303-8.

**How to cite this article:** Kokila M, Pai VS, Krishna S, Kalladka G, Rajaram S, Goankar S. Comparison of the rate of maxillary canine retraction with or without modified corticotomy facilitated orthodontic treatment. *J Global Oral Health* 2021;4(1):8-9.