

splint therapy is useful for the diagnosis and management of various masticatory system disorders.^[2] Occlusal adjustment involves repositioning the mandible to a centric occlusion using orthodontic appliances. Intraoral occlusal splints are designed to provide even and balanced occlusion without forcefully altering the mandibular rest position. A splint is worn on the teeth such as a retainer or a removable denture.

OCCLUSAL SPLINTS AND THEIR TYPES

“Splint” can be several apparatus, appliances, or devices employed to provide stabilization or support of teeth or bones, or generally to resist motion or displacement of fractured or injured structures (Glossary of orthodontic terms).^[3]

“Occlusal splint therapy can be defined as the art and science of establishing neuromuscular harmony in the masticatory system by creating a mechanical alteration of centric occlusion with a removable appliance.”^[4]

“An occlusal splint is a removable appliance which covers the occlusal surfaces of the teeth in either the maxillary or mandibular arches [Figure 1]. The ideal occlusal splint is made from acrylic resin which should cover the occlusal surfaces of all the teeth in one arch or both arches.” It is also called an occlusal appliance, interocclusal appliance, bite guard, and night guard.

TYPES OF OCCLUSAL SPLINTS

According to Dawson splint classification

1. Permissive splints/muscle deprogrammer.
2. Non-permissive splints/directive splints
3. Pseudo permissive splints (e.g., Soft splints and hydrostatic splints).

Permissive Splints/muscle deprogrammer

The permissive splints allow the teeth to glide unhindered over the biting or contact surface.^[5] The primary function of these splints is to alter the occlusion so that the teeth do not interfere with the complete seating of the condyles and to control muscle forces. Hence, these splints are also called

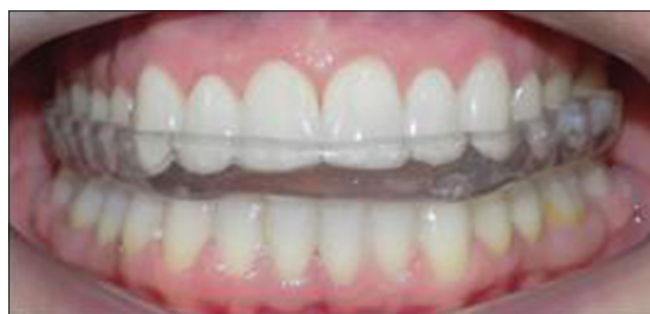

Figure 1: Intraoral maxillary occlusal splint.

muscle deprogrammers and represent the flat plane appliance. The two classic designs of permissive splints are anterior midpoint contact splints [Figure 2] (anterior bite planes and anterior deprogrammer) and full contact splints [Figure 3] (centric relation, flat plane, tanner, and superior repositioning) [Figures 2 and 3].

Non-permissive splints/directive splints

Non-permissive splints do not allow free movements of the mandible. These have slopes or indentations on the occluding surface that helps in limiting the movements of the mandible. These are also called “directive splints,” because these appliances guide the mandible in a specific relationship to the maxilla. The sole purpose of the directive splint is to position or align the condylar-disk assemblies to a more stable position. It includes an anterior repositioning appliance and a mandibular repositioning appliance.

Pseudo permissive splints

Two splints are given below, that is, soft splints and hydrostatic splints are considered pseudo-permissive

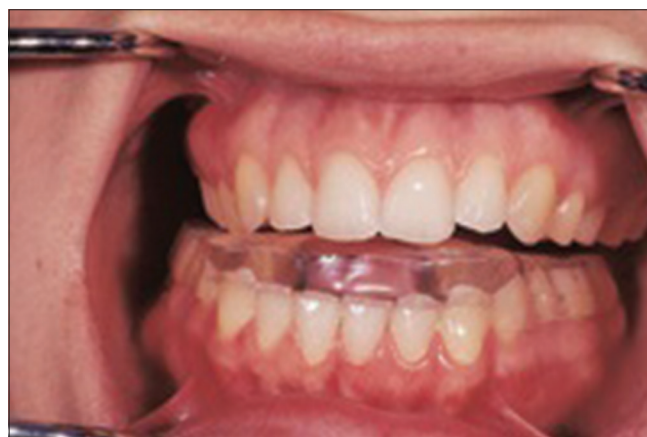

Figure 2: Anterior midpoint contact splint.

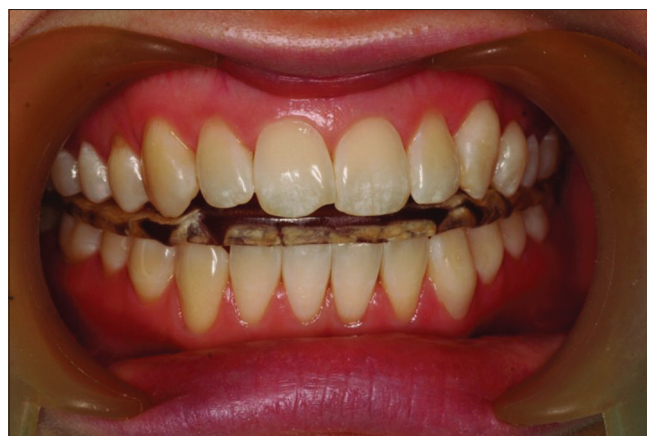

Figure 3: Full contact splint.

splints. These splints can exacerbate bruxism, possibly due to premature posterior contacts associated with the very fact that these splints cannot be balanced.^[6]

Hydrostatic appliance

It has a bilateral water-filled chambers on posterior teeth, thereby giving cushioning effect to redistribute the occlusal forces. These chambers are attached to the acrylic palatal plates. These splints are working based on a new application of a physical law of nature called Pascal's Law, which states that an enclosed fluid will apply equalized fluid pressure regardless of the shape of the splint. It employs water to balance the biting pressure, treat malocclusion, and relieve TMJ pain and symptoms associated with TMDs.^[7,8] It is inserted either in the upper or lower jawbone.^[8] Its commercial name is Aqualizer. It is available as Aquasplint mini, Aquasplint classic, and Aquasplint ultra [Figure 4].

Soft rubber splint [Figure 4]

The soft appliance is a device fabricated of resilient material that is usually adapted to the maxillary teeth [Figure 5]. These appliances have been recommended for patients who experience high levels of clenching and bruxism which will reduce pain, discomfort, and myalgia of joints. However, these appliances can exacerbate the bruxism probably due to the inability to achieve balanced contact with posterior teeth.^[9]

FUNCTIONS OF OCCLUSAL SPLINTS [FIGURE 5]

Fabricated splints have six functions, including the following:

- (1) To relax the muscles,
- (2) To maintain centric relations,
- (3) To provide diagnostic information,
- (4) To protect the occlusal surfaces teeth and associated structures from bruxism,

- (5) To mitigate periodontal ligament proprioception, and
- (6) To reduce cellular hypoxia levels.

RELAXING THE MUSCLE

The bite force is considered an important indicator of masticatory function, which is exerted by the elevator muscles and is regulated by the nervous, muscular, skeletal, and dental systems. Therefore, the muscle spindle plays the most important role in relaxing the muscle during occlusal splint therapy. Masseter and anterior temporalis muscle and its muscle spindle show a high degree of functional adaptability after splint therapy. Muscle spindles play a role in maintaining the posture of the mandible (Brill and Tryde, 1974; Broekhuijsen and van Willigen, 1983) and jaw movements during masticatory function. Therefore, jaw muscle spindles could be the receptors responsible for the perception and maintenance of the occlusal vertical dimension (OVD) and the control of jaw movements during normal masticatory function.^[10] Most splints alter the vertical dimension of occlusion and increase the functional length of muscles. The muscular length develops maximum tension at the resting position. The vertical dimension at the clinical rest position (postural position) has a minimal muscle strain. The elevator muscles are presumed to be the most relaxed at rest. The nature of the occlusal system and specific tooth contact influences muscle function while opening and closing the jaw.

The splint therapy can control teeth interferences and mandibular movement. This will modify the muscle hyperactivity by helping the OVD masticatory muscle get relaxed. The tooth interferences to the centric relation arc of closure activate the lateral pterygoid muscles.^[11] Posterior tooth interferences during excursive mandibular movements cause hyperactivity of the closing muscles (masseter, temporalis, and medial pterygoid).^[12] A muscle that is in a fatigued and hyperactive state can present with pain.

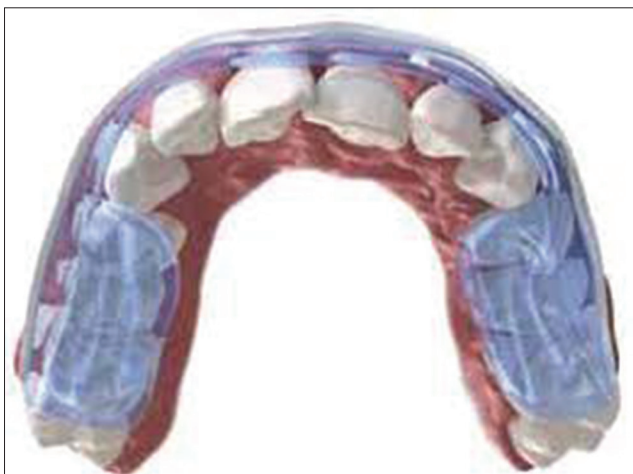


Figure 4: Hydrostatic occlusal splint.

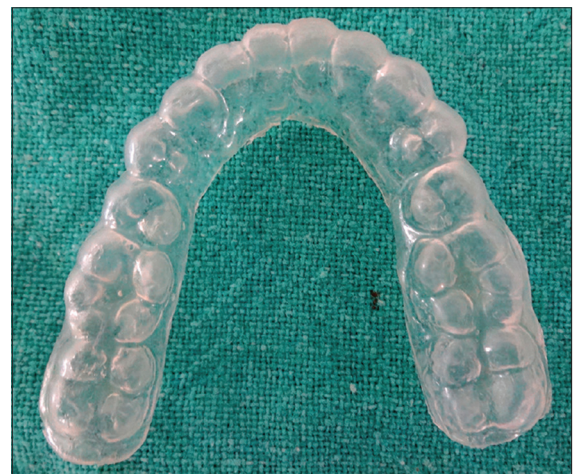

Figure 5: Soft splint.

Occlusal splint promotes the elimination of posterior excursive contacts by anterior guidance and condylar guidance which will relax the elevator muscle and positioning muscle allowing the condyles to seat in centric relation: For the condyles to seat completely under the articular disk in the anterosuperior position, the superior belly of the lateral pterygoid should obtain its full extension. When the lateral pterygoid is triggered to hyperactivity through occlusal force, the disk is pulled anteromedially toward the origin of the muscle, resulting in displacement. Overloading of condyle/disk assembly when not in normal physiologic position contributes to TMJ disorders. A properly balanced splint results in an occlusion associated with relaxed positioning and elevator muscles, allowing the articulator disk to obtain its anterosuperior position over the condylar head. Thereby, chronic symptoms of muscle hyperactivity were lessened significantly within 24-h of splint wear. The effectiveness of splint therapy in reducing pain indexes and muscle hyperactivity is well documented^[13-16] from the 1st day to 8 weeks time period.

TO MAINTAIN THE CENTRIC RELATION

The basic function of the occlusal splint is to prevent the existing occlusion from controlling the maxillomandibular relationship at maximum intercuspation (centric relation). The Glossary of Prosthodontic Terms defines centric relation as “A clinically determined maxilla-mandibular relationship, in which condylar disk articulate in their anterosuperior position in the mandibular fossae and against the distal slope of the articular eminence.”^[17] Splint therapy can utilize centric relation as a physiologic treatment position. Whenever rearrangement of the occlusion is required, it is essential to do restorative procedures with a period of splint therapy to ensure that a stable relationship has been obtained.

PROVIDE DIAGNOSTIC INFORMATION

Splint therapy can be an important diagnostic tool to determine wear patterns, bruxism habits, and the anatomic and physiologic status of the joint and TMD status.^[18] If a patient becomes comfortable with a splint immediately, it may be an indication that the disorder is muscular. If symptoms worsen with permissive splint wear, this may indicate an internal disk derangement problem or an error in the initial diagnosis.^[4]

PROTECTING OCCLUSAL SURFACES OF TEETH AND ASSOCIATED STRUCTURES FROM BRUXISM

Patients who are prone to nocturnal bruxism (the grinding or clenching of teeth) should routinely wear occlusal splints at night because the splints protect the teeth against wear as

the wear occurs against the splint. Furthermore, the splints reduce stress on the individual tooth due to more teeth contacts of equal intensity.^[19] It is important to remember that splints do not prevent night grinding; rather, they distribute the force across the masticatory system. These appliances can decrease the frequency but not the intensity of the bruxing episodes.^[20]

MITIGATING PERIODONTAL LIGAMENT PROPRICEPTION

Proprioceptive fibers contained in the periodontal ligament of each tooth send messages to the central nervous system, triggering muscle patterns that protect them from overload. An occlusal splint functions to dissipate the forces placed on individual teeth by utilizing a larger surface area covering all teeth in the arch. Thus, a splint balances the proprioception and allows for muscle symmetry.^[21] Hannam *et al.*^[22] also found that in cats, stimulation of pressure receptors in the periodontal membrane led to a jaw-opening reflex. This helps in clarifying why the teeth must be kept in balance with the condylar disk assembly to maintain neuromuscular functions in the associated muscles.

REDUCING CELLULAR HYPOXIA LEVELS

In a study by Nitzan,^[23] pressure was measured in the superior joint space of patients with articular disk displacements. While clenching maximally, recorded pressures reached up to 200 mm Hg. When a flat plane appliance was placed, no significant pressure (no capillary hyper fusion pressure) was recorded.

CHOOSING THE CORRECT OCCLUSAL SPLINT

Determination of the appropriate type of splint therapy depends on the specific diagnosis of TMD.

1. If the patient reports bruxism and headaches, the use of a full-coverage splint at night, in which acrylic covers an entire arch of teeth, is often adequate to protect the teeth. A minimum of a 4-mm splint thickness increase in vertical dimension is necessary to protect bruxism patients. If the patient is wearing a 4 mm thickness splint and still experiences muscular tenderness, headache, and/or facial muscle tightness immediately after waking, splint thickness should be increased incrementally until symptoms disappear^[4,24] When a muscle disorder is suspected in TMD patients, minimal invasive may be used like bite planes which will separate the teeth and allowing the muscles to relax. In general, muscle disorders are effectively treated with appropriate splint therapy (bite planes and stabilization appliances).^[4,18,24]
2. If the combination of muscle and disk disorders is identified (i.e., clicking sound with muscle pain),

stabilization bite splints are the treatment of choice. They provide long-term wear and also cover the entire dental arch, ensuring that the covered teeth do not move. If advanced disk and muscle disorders are identified (jaw locking and/or noises, painful joints), stabilization splints are the treatment of choice, they must be worn continually for 24 h for as long as required to eliminate the muscle, disk, ligament, and tooth symptoms. 3 to 6 months of wear is required depending upon the patient.^[24]

- In acute trauma, an anterior repositioning appliance for 7–10 days is required to keep the condyle away from the retrodiscal tissues so that the inflammation can subside.

CONCLUSION

This article is a review of different types of splints that can be given to TMD patients for different problems and selecting proper splints dentist should have a thorough understanding of symptoms and carry out a complete assessment of TMJ and its associated problems. A perfect appliance with fewer complications should be delivered.

Declaration of patient consent

Patient's consent not required as there are no patients in this study.

Financial support and sponsorship

Nil.

Conflicts of interest

There are no conflicts of interest.

REFERENCES

- Seifeldin SA, Elhayes KA. Soft versus hard occlusal splint therapy in the management of temporomandibular disorders (TMDs). *Saudi Dent J* 2015;27:208-14.
- Kreiner M, Betancor E, Clark GT. Occlusal stabilization appliance. Evidence of their efficacy. *J Am Dent Assoc* 2001;132:770-7.
- Jacobson A. Glossary of orthodontic terms. *Am J Orthod Dentofacial Orthop* 2002;122:335.
- Dylina TJ. A common sense approach to splint therapy. *J Prosthet Dent* 2001;86:539-45.
- Boero RP. The physiology of splint therapy: A literature review. *Angle Orthod* 1989;59:165-80.
- Okeson JP. Management of Temporomandibular Disorders and Occlusion. Amsterdam, Netherlands: Elsevier Health Sciences; 2019.
- Lerman MD. A complete hydrostatically derived treatment of TMJ pain dysfunction syndrome. *J Am Dent Assoc* 1974;89:1351-7.
- Lerman MD. The hydrostatic appliance: A new approach to the treatment of the TMJ pain-dysfunction syndrome. *J Am Dent Assoc* 1974;89:1343-50.
- Okeson JP. The effects of hard and soft occlusal splints on nocturnal bruxism. *J Am Dent Assoc* 1987;114:788-791.
- Yabushita T, Zeredo JL, Fujita K, Toda K, Soma K. Functional adaptability of jaw-muscle spindles after bite-raising. *J Dent Res* 2006;85:849-53.
- Ramford S, Ash M. Occlusion. 3rd ed. Philadelphia, PA: WB Saunders Co.; 1983.
- Manns A, Rocabado M, Cadenasso P, Miralles R, Cumsille MA. The immediate effect of the variation of anteroposterior laterotrusive contact on the elevator EMG activity. *Cranio* 1993;11:184-91.
- Manns A, Miralles R, Guerrero F. The changes in the electrical activity of the postural muscles of the mandible upon varying the vertical dimension. *J Prosthet Dent* 1981;45:438-45.
- Manns A, Miralles R, Santander H, Valdivia J. Influence of the vertical dimension in the treatment of the myofascial pain-dysfunction syndrome. *J Prosthet Dent* 1983;50:700-9.
- Clark GT, Lanham F, Flack VF. Treatment outcome results for consecutive TMJ clinic patients. *J Craniomandib Disord* 1988;2:87-95.
- Sheikholeslam A, Holmgren K, Riise C. A clinical and electromyographic study of long-term effects of an occlusal splint on the temporal and masseter muscles in patients with functional disorders and nocturnal bruxism. *J Oral Rehabil* 1986;13:137-45.
- Williamson EH, Lundquist DO. Anterior guidance and its effect on electromyographic activity of the temporal and masseter muscles. *J Prosthet Dent* 1983;49:816-23.
- The glossary of prosthodontic terms. *J Prosthet Dent* 1999;81:39-110.
- Yunus N. Occlusal splints therapy: A review. *Indian J Dent Educ* 2009;2:5.
- Holmgren K, Sheikholeslam A, Riise C. Effect of a full arch maxillary occlusal splint on parafunctional activity during sleep in patients with nocturnal bruxism and signs and symptoms of craniomandibular disorders. *J Prosthet Dent* 1993;69:293-7.
- Srivastava R, Jyoti B, Devi P. Oral splint for temporomandibular joint disorders with revolutionary fluid system. *Dent Res J (Isfahan)* 2013;10:307-13.
- Hannan AG, Wood WW, De Cou RE, Scott JD. The effects of working side occlusal interferences on muscle activity and associated jaw movements in man. *Arch Oral Biol* 1981;26:387-92.
- Nitzan DW. Intraarticular pressure in the functioning human temporomandibular joint and its alteration by uniform elevation of the occlusal plane. *J Oral Maxillofac Surg* 1994;52:671-9.
- Piper M. Manual for Intermediate to Advanced TMD Treatment. St. Petersburg, FL: Center for Advanced Dental Study; 1999. p. 1-17.

How to cite this article: Ramalingam S, Saravana Priyan GL. Occlusal splint therapy in TMD pain management: A review. *J Global Oral Health* 2022;5:102-6.